



ANTI-INFLAMMATORY EFFECT OF GINGER IN RAT

Mona A. El Shemy^a, Abdalla, A.O.^b and Fararh, K.M.^a

^a Clinical Pathology Dept., Fac. Vet. Med., Benha University, ^b Clinical Pathology Dept., Fac. Vet. Med., Suez Canal University.

ABSTRACT

Sixty male albino rats were divided into four groups (n=15 per group). Group one was used as a control. Group II (ginger group) was administered 400 mg ginger/kg body weight. Group III (malathion group) was administered 100 mg malathion/kg body weight. Group IV (ginger protected group) was given ginger two weeks before administration of malathion. Results showed that there was a significant reduction in the nuclear factor kappa beta expression, ALT, AST and cholesterol in ginger protected group when compared to malathion group. Furthermore, there was a significant increase in albumin and total protein in ginger protected group when compared to control group. The histopathological examination of the liver revealed slight congestion and dilatation of central vein in ginger protected group compared to malathion group which showed hydropic degeneration of the hepatocytes with focal areas of coagulative necrosis. These results confirmed that ginger is a strong anti-inflammatory and anti-hepatotoxic agent in rats treated with malathion.

KEY WORDS: Anti-inflammatory, Ginger, Malathion, Rat.

(BVMJ 22(2): 249-256, 2011)

1. INTRODUCTION

Inflammatory disorders not only caused by infectious agents but also can be caused by free radicals. Free radicals are constantly produced in the body. When these free radicals produced greater than detoxification capacity of the cells, (as in malathion toxicity) excessively generated reactive oxygen species (ROS) cause extensive damage to the liver cells and act as a mediator of pro-inflammatory events. The liver is an important organ which is actively involved in many metabolic functions and is the frequent target for a number of toxicants. Hepatic damage is associated with distortion of these metabolic functions [14].

Although nuclear factor kappa beta (NF-KB) is expressed in an inactive state in most cells, many studies have linked the activation of nuclear transcription factor kappa beta with variety of inflammatory diseases. Thus, the decrease in the NF-KB

signaling pathway expression might be a therapeutic strategy in conjugation with the usage of anti-inflammatory drugs [1].

NF-KB is activated by free radicals, inflammatory stimuli, carcinogens, tumor promoters, endotoxin, radiation, ultraviolet (UV) light, and x-rays. On activation, NF-KB induces the expression of more than 200 genes that have been shown to suppress apoptosis and induce cellular transformation, proliferation, invasion, metastasis, chemo-resistance, radio-resistance and inflammation. The activated form of NF-kB has been found to mediate cancer [2].

Extensive researches in the last few years have shown that the pathway that activates this transcription factor can be interrupted by phytochemicals derived from spices such as ginger [6]. Ginger has been used as a cure for many diseases including inflammatory diseases. Ginger contains

active phenolic compounds such as gingerol, paradol and shogol that have strong anti-inflammatory effect. It has also been shown to down regulate NF-KB pathway [10]. Recently, it has been shown that ginger is effective against cytokines synthesized and secreted at sites of inflammation. Therefore, the present study was designed to examine the anti-inflammatory and antihepatotoxic effects of ginger in malathion-induced hepatitis.

2. MATERIAL AND METHODS

2.1. *Animals*

Sixty male albino rats with average body weight 125 g were used in this study. Rats were obtained from United Co. for Chemical and medical preparation, Cairo, Egypt. Animals were housed in separate metal cages. Fresh and clean drinking water was supplied *Ad libitum*. The animals were left for 15 days for acclimatization before the beginning of the experiment. Rats were kept at constant environmental and nutritional condition throughout the period of experiment.

2.2. *Ginger dosage:*

Ginger was obtained as tablet from MEPACO pharmaceutical company and administrated intra-gastric using stomach tube at a dose of 400 mg/kg B.Wt. once daily [3].

2.3. *Malathion:*

Malathion was administrated intra-gastric using stomach tube at a dose of 100 mg/kg B.Wt. once daily [18].

2.4. *Sampling*

Blood samples were obtained from the retro-orbital venous plexus at the end of second week, after that the samples were collected by sacrificing at the 4th and 6th week. Blood was collected into plain centrifuge tube to separate serum for biochemical analysis (ALT, AST, Total protein, albumin and cholesterol).

Biochemical kits for determination of transaminase activities (ALT, AST), serum total protein, albumin and cholesterol were obtained from Stanbio laboratory. At the end of the 6th week, the rats were sacrificed for tissue sampling. Liver specimens were fixed in 10% neutral buffered formalin for immunohistochemical staining and histopathological examination.

2.5.1. *Immunohistochemistry staining protocol:*

Tissue sections were de-paraffinized and hydrated by sequential immersion in xylene, graded alcohol solutions (100%, 95%, 80% and 70%) for three minutes at each concentration and running water for three minutes. Then sections were incubated in 3% hydrogen peroxide for 10 min to block the activity of endogenous peroxidases. Sections were washed with TRIS-buffered saline (TBS) before immersion in Target Retrieval Solution (TRS) (DAKO, U.S.A.) for 20 minutes in a water bath at 98°C. To reduce the background staining, the slides were immersed in biotin and avidin solution for 30 min. before being blocked with Bovine Serum Albumin (BSA) to reduce the non-specific staining and incubation with the primary antibody at different concentrations (1:50, 1:100, 1:200, 1: 400, 1:500, 1:600 and 1:1000) overnight at 4°C. The sections were washed three times with TBS for three minutes each before incubating for 30 minutes with the secondary antibody conjugated with biotin and subsequently with Streptavidin-HRP (anti-mouse, anti-rabbit and anti-rat LSAB + System-HRP kit, DAKO, USA). The sections were washed again with TBS before finally incubating with DAB for 10 minutes. The sections were counterstained with Meyer's Haematoxylin and mounted with DPX for viewing of the slides.

2.5.2. *Immunostaining analysis:*

Immunoreactivity evaluation was based on percentage of positive staining

of nuclear factor kappa beta. The mean percentage of positive staining cells was determined by counting 1000 stained cells at 10 different fields using a light microscope ($\times 40$) [21].

2.6. Statistical analysis:

The obtained data were analyzed with the statistical software package SPSS for Windows (version 11.0, SPSS Inc., Chicago, USA). Statistical analysis was carried out with one way ANOVA test [23].

3. RESULTS

3.1. Ginger group compared to control group:

Concerning to the expression of nuclear factor kappa beta, there was no significant change at the 6th week of age (Table 1). Regarding to ALT, AST, total protein and albumin, our results confirmed that there were no significant changes at the 2nd, 4th and 6th week of age. Cholesterol level showed no significant change at the 2nd and 4th week of age. Meanwhile, a significant decrease was observed at the 6th week of age (Tables 2-4). Histopathological examination of liver revealed normal histological appearance of the hepatocytic parenchyma similar to the control group.

3.2. Malathion group compared to control group:

The expression of nuclear factor kappa beta was significantly increased at the 6th week of age (Table 1, Photo 1). Concerning to ALT, AST and cholesterol, our results showed that there was significant increase at the 2nd, 4th and 6th week of age. Meanwhile, there was significant decrease in total protein at the 2nd, 4th and 6th week of age. Albumin showed no significant change at the 2nd and significant decrease was observed at

the 4th and 6th week of age. Histopathological examination of liver showed congestion of the central and portal veins, the portal areas were expanded by moderate numbers of inflammatory cells and marked proliferation of the lining epithelial cells of bile ducts (Photo 3). Multifocal vacuolar and hydropic degeneration of the hepatocytes particularly in the periportal areas of the hepatic lobules were common (Photo 4). Small focal areas of coagulative necrosis characterized by retention of hepatocytes architecture with pyknosis or absence of the nuclei and homogenous eosinophilic cytoplasm were seen admixed with erythrocytes (Photo 5).

3.3. Ginger protected group compared to malathion group:

Nuclear factor kappa beta expression, showed significant decrease in at the 6th week of age (Table 1, Photo 2). Regarding to ALT, AST and cholesterol, there was significant decrease in ALT, AST and cholesterol at the 2nd, 4th and 6th week of age. Total protein showed significant increase at the 2nd, 4th and 6th week of age. Albumin showed no significant change at the 2nd week of age while there was significant increase of albumin at the 4th and 6th week of age. Histopathological examination of liver revealed that there was mild vacuolar and hydropic degeneration of some hepatocytes around the portal areas (Photo 6).

Table 1 Nuclear factor kappa beta expression in Control, Ginger, Malathion and ginger protected groups after 6 weeks of treatment

Animal groups	Nuclear factor kappa beta (%)
Control	10.00 \pm 0.09 ^a
Ginger	10.00 \pm 0.07 ^a
Malathion	80.00 \pm 0.07 ^b
Ginger + Malathion	20.00 \pm 0.29 ^c

Means (\pm S.E.) with different superscripts (a, b, c) within the same column were significantly different ($P < 0.05$).

Table 2 Changes in biochemical parameters (ALT, AST, Cholesterol, total protein and albumin) in Control, Ginger, Malathion and ginger protected groups after 2 weeks of treatment.

Animal groups	ALT (U/l)	AST (U/l)	Cholesterol (mg/dl)	Total Protein (g/dl)	Albumin (g/dl)
Control	21.44±0.80 ^a	47.66±0.92 ^a	48.78±1.56 ^a	5.50±0.38 ^a	2.40±0.24 ^a
Ginger	22.02±1.14 ^a	45.76±1.14 ^a	44.66±1.45 ^a	5.70±0.26 ^a	2.40±0.42 ^a
Malathion	29.06±0.37 ^b	60.02±0.26 ^b	84.90±1.55 ^b	4.60±0.41 ^b	3.04±0.28 ^a
Ginger + Malathion	21.70±0.73 ^{ac}	45.52±0.95 ^{ac}	46.64±1.42 ^c	5.74±0.11 ^{ac}	2.96±0.30 ^a

Means (±S.E.) with different superscripts (a, b, c) within the same column were significantly different (P<0.05).

Table 3 Changes in biochemical parameters (ALT, AST, Cholesterol, total protein and albumin) in Control, Ginger, Malathion and ginger protected groups after 4 weeks of treatment.

Animal groups	ALT (U/l)	AST (U/l)	Cholesterol (mg/dl)	Total Protein (g/dl)	Albumin (g/dl)
Control	21.94±0.69 ^a	45.60±0.89 ^a	52.84±1.41 ^a	6.00±0.16 ^a	3.02±0.16 ^a
Ginger	21.82±0.74 ^a	43.34±0.53 ^a	51.74±0.82 ^a	6.12±0.26 ^a	3.02±0.16 ^a
Malathion	49.62±0.56 ^b	61.18±0.29 ^b	94.48±1.92 ^b	4.04±0.24 ^b	2.66±0.11 ^b
Ginger + Malathion	26.04±0.95 ^c	49.50±0.42 ^c	65.66±1.33 ^c	6.04±0.29 ^{ac}	3.04±0.13 ^{ac}

Means (±S.E.) with different superscripts (a, b, c) within the same column were significantly different (P<0.05).

Table 4 Changes in biochemical parameters (ALT, AST, Cholesterol, total protein and albumin) in Control, Ginger, Malathion and ginger protected groups after 6 weeks of treatment.

Animal groups	ALT (U/l)	AST (U/l)	Cholesterol (mg/dl)	Total Protein (g/dl)	Albumin (g/dl)
Control	20.08±0.09 ^a	45.24±1.00 ^a	55.66±1.66 ^a	6.48±0.26 ^a	3.14±0.18 ^a
Ginger	20.16±0.07 ^a	45.44±0.84 ^a	50.60±0.68 ^b	6.68±0.16 ^a	3.22±0.24 ^a
Malathion	50.28±0.22 ^b	61.02±0.36 ^b	100.9±1.16 ^c	3.94±0.21 ^b	2.84±0.17 ^b
Ginger + Malathion	23.72±1.08 ^c	47.18±0.74 ^{ac}	60.34±0.76 ^d	6.26±0.19 ^{ac}	3.00±0.19 ^{ac}

Means (±S.E.) with different superscripts (a, b, c) within the same column were significantly different (P<0.05).

4. DISCUSSION

Ginger has long been used in traditional medicine as a cure for many diseases including inflammatory disease [1]. Ginger contains active phenolic compounds such as gingerol, paradol and shagoals that have anti-inflammatory properties. It has also been shown to down-regulate the nuclear factor kappa beta (NF-KB) therefore, ginger may be used to control many inflammatory diseases [11].

The present study investigated that there was no significant change in the expression of NF-KB in ginger group compared with control group. Meanwhile, significant increase in the NF-KB expression was occurred in malathion group when compared to control group. It was found that malathion induces the production of hydrogen peroxide that activates the transcription of NF-KB [19]. The protection by ginger prior to

malathion showed significant reduction in the expression of NF-KB. These results supported by the results of Habib *et al.* [9] who found that ginger has anti-inflammatory and anticancer effects through its ability to block the elevated expression of NF-KB in the liver of rats. Similar investigations by previous authors [2, 8, 13, 17] showed that the inhibitory effect of ginger on nuclear factor kappa beta pathway. Topical application of 6-gingerol suppressed nuclear factor kappa beta DNA binding activity. Ginger may block steps in the NF-KB pathway, such as signals that activate the NF-KB signaling cascade, translocation of the nuclear factor kappa beta into the nucleus, DNA binding of dimers or interactions with the basal transcriptional pathway.

Concerning liver transaminases, there were significant increases in both ALT and AST in malathion group when compared to control group. These data are a sensitive

index of hepatic damage which is supported by histopathological examination of liver revealed multifocal vacuolar and hydropic degeneration of the hepatocytes. The degenerated hepatocytes exhibited marked enlargement of the cells by multiple small round empty vacuoles that distend the cell cytoplasm, while the sinusoids were diffusely collapsed and bloodless. Occasionally, diffuse vacuolar and hydropic degeneration of the hepatocytes and small focal areas of lymphocytic cellular aggregation in

between the hepatocytes were noticed in some cases. Small focal areas of coagulative necrosis characterized by retention of hepatocytes architecture with pyknosis or absence of the nuclei and homogenous eosinophilic cytoplasm were seen admixed with erythrocytes. Moreover, large areas of lytic necrosis characterized by loss of hepatocytes and an influx of erythrocytes and eosinophilic material (edema) into the vacant space were also detected adjacent to the portal areas.

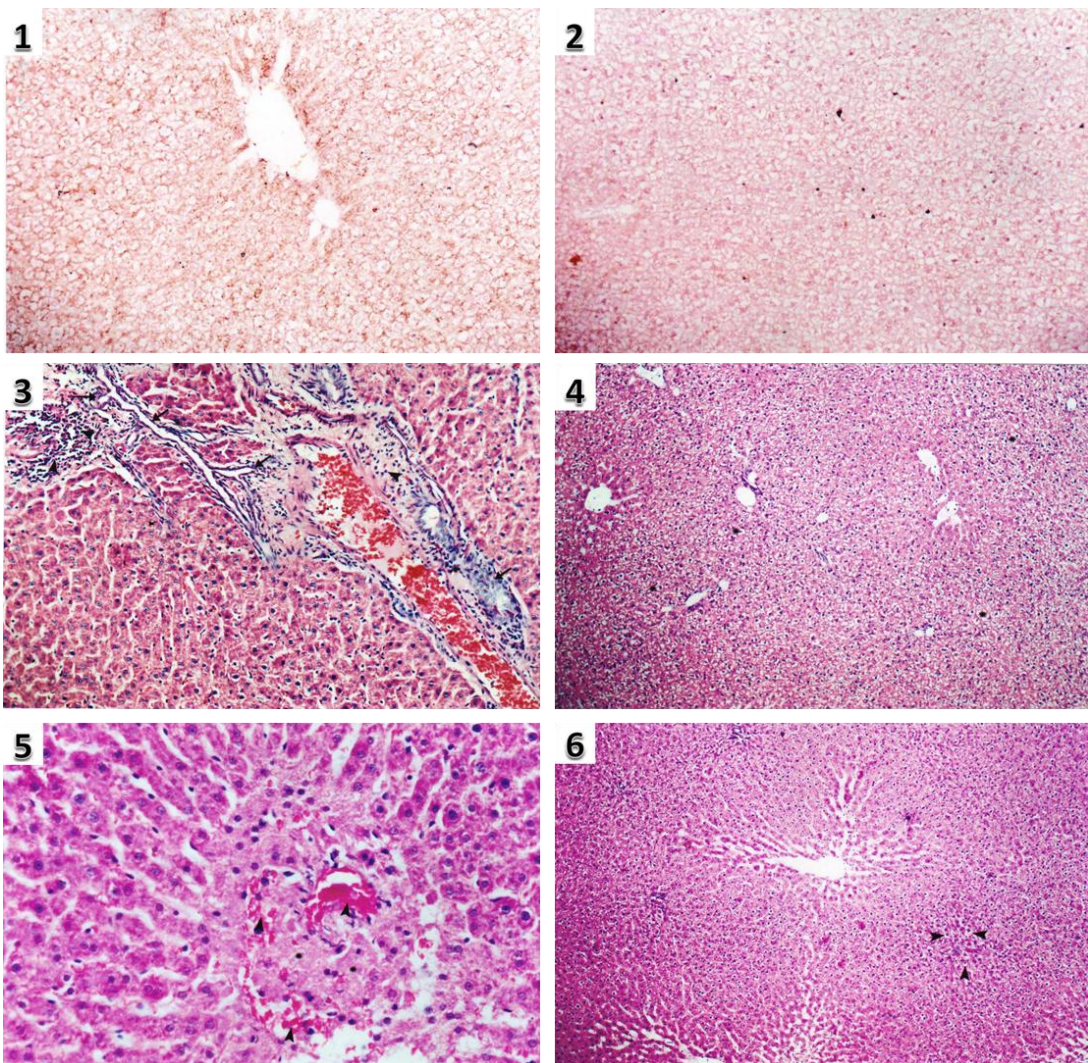


Photo 1 Liver of malathion treated rats showing high expression of NF-KB ($\times 200$). Photo 2 Liver of ginger protected rats showed low expression of NF-KB ($\times 200$). Photo 3 Liver of malathion treated rat showing congestion of portal vein, with inflammatory cellular infiltration of the portal areas and marked proliferation of the lining epithelial cells (arrow) of bile ducts (H&E stain, $\times 200$). Photo 4 Liver of malathion treated rat showing multifocal periportal areas of vacuolar and hydropic degeneration of the hepatocytes (H&E stain, $\times 100$). Photo 5 Liver of malathion treated rat showing small focal area of coagulative necrosis (asterisk) admixed with erythrocytes (arrow head) (H&E stain, $\times 400$). Photo 6 Liver of ginger protected rat showed mild vacuolar and hydropic degeneration (arrow head) of some hepatocytes (H&E stain, $\times 100$).

These observations indicated marked changes in the liver histo-architecture in response to malathion. Normally, the reactive metabolites are detoxified by hepatic glutathione. When hepatic glutathione becomes exhausted, these metabolites bind to liver macromolecules resulting in hepatocyte damage in addition to the damage caused by free radical generation [4]. These histopathological results agree with Mahmoud *et al.* [15]. In contrast to these results, the protection by ginger before malathion administration showed significant decrease in both ALT and AST when compared to malathion group which is reflected by mild histopathological change in the liver. These results support the result of Mahmoud *et al.* [15] and Atta *et al.* [5] who showed the hepatoprotective action of ginger against malathion. In the present study the serum proteins and albumin showed significant decrease in malathion group when compared to control group. These results were ascertained by Al-Attar [4] and Mahmoud *et al.* [15] who found that there were significant decreases in both total protein and albumin in malathion toxicity which may be due to changes in protein and free amino acids metabolism and their synthesis in liver and also due to damaging effect of malathion on liver cells. The decrease in protein may be due immunosuppressive effect of malathion [7]. It was found that protection with ginger before malathion administration significantly increase total protein and enhance the albumin synthesis when compared to malathion group. Our results are in agreement with Norina *et al.* [16] and Ezeonu *et al.* [7] who recorded that there was significant increase in both total protein and albumin. Regarding cholesterol, malathion administered rats showed significant increase in cholesterol level when compared to control group. These results confirmed by histopathological examination of the liver revealed that the

portal areas were expanded by moderate numbers of inflammatory cells and marked proliferation of the lining epithelial cells of bile ducts. Elevation in cholesterol level may be attributed to the increased hydroxymethylglutaryl Co A reductase activity which is the rate limiting enzyme in cholesterol synthesis in tissues [20]. Ginger group showed significant decrease in cholesterol level when compared to control group. Furthermore, protection with ginger before malathion administration showed significant decrease in cholesterol level when compared to malathion group. These findings are in accordance with Kadnur and Goyal [12] who recorded that ginger significantly decreases the level of cholesterol in rats given high doses of fructose supplemented diet to produce significant elevation of cholesterol. This antihypercholesterolemic effect of ginger may be due to enhancement of the catabolism of cholesterol to bile acids and inhibition of cholesterol synthesis [22].

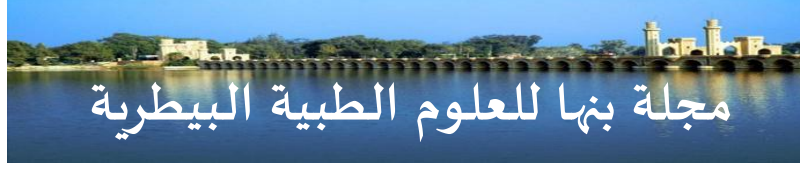5. CONCLUSION

It is concluded that the consumption of ginger in diet protects the liver against damage caused by malathion as ginger significantly ameliorates malathion induced inflammation.

6. REFERENCES

1. Afzal, M., Al-Hadidi, D., Menon, M., Pesek, J. and Dhami, M. 2001. Ginger: an ethnomedical, chemical and pharmacological. *Drug Metabol Drug Interact* **18**: 159-190.
2. Aggarwal, B. and Shishodia, S. 2006. Molecular targets of dietary for prevention and therapy of cancer. *Biochem Pharmacol.* **71**: 1397-1421.
3. Ajith, T.A., Nivitha, V. and Usha, S. 2007. Zingiber officinale roscoe alone and in combination with alpha-tocopherol protect the kidney against

- Cisplatin induced acute renal failure. *Food Chem. Toxicol.* **45**: 921-927.
4. Al-Attar, A.M. 2010. Physiological and histopathological investigations on the effects of alpha lipoic acid in rats. *J Biomed. Biotechnol.* **503**: 201-209.
 5. Atta, A.H., Elkoly, T.A., Mounair, S.M., Kamel, G., Alwabel, N.A. and Zaher, S. 2010. Hepatoprotective effect of methanol extract of zingiber officinale and cichorium intybus. *Indian J. Pharm. Sci.* **72**: 564-570.
 6. Bharath, A. and Shishir, S. 2004. Suppression of nuclear factor-KB activation pathway by spice derived phytochemicals. *Ann. N.Y Acad. Sci.* **1030**: 434-441.
 7. Ezeonu, C., Egbuna, P.A, Ezeanyika, L.U., Nkwonta, C.G. and Idoko, N.D 2011. Antihepatotoxicity studies of crude extract of zingiber officinale on CCL4 induced toxicity and comparison of the extracts fraction D hepatoprotective capacity. *Res. J. Med. Sc.* **5**: 102-107.
 8. Garg, A. and Aggarwal, B. 2002. Nuclear 2 transcription factor-KB as a target for cancer drug development. *Leukemia.* **16**: 1053-1068.
 9. Habib, S.H., Makpols, A. H., Das, N.A., Ngah, S. and Yusof, W.Z. 2008. Ginger extract (Zingiber officinal) has anticancer and anti-inflammatory effects on ethionine induced hepatoma rats. *Clinics* **63**: 807-813.
 10. Hudson, E., Fox, L., Luckett, J. and Manson, M. 2006. Ex. Vivo cancer chemoprevention research possibilities. *Environ. Toxicology Phar.* **21**: 204-214.
 11. Jeyakumar, S., Nalini, N. and Menon, V. 1999. Antioxidant activity of ginger (Zingiber officinale) in rats fed a high fat diet. *Med. Sci. Res.* **27**: 341-344.
 12. Kadnur, S. and Goyal, R. 2005. beneficial effects of Zingiber Officinale Roscoe on fructose induced hyperlipidemia and hyperinsulinemia in rats. *Indian J. Exp. Biol.* **43**: 1161-1164.
 13. Kim, S., Chun, K., Kundu, J. and Surh, Y. 2004. Inhibitory effects of 6-gingerol on PMA- induced COX-2 expression and activation of NF- KB in skin mouse. *Bio Fac.* **21**: 27-31.
 14. Kowaltowski, A. and Vercesi, A. 2000. Mitochondrial damage induced by conditions of oxidative stress. *Free Radio Biol. Med.* **26**: 463-471.
 15. Mahmoud, A., Thanaa, A., Ashraf, M. and Mohamed, A. 2010. potential hepatoprotective effects of vitamin E and Nigella sativa oil on hepatotoxicity induced by chronic exposure to malathion in human and male albino rats. *Toxicol. Exp. Chem.* **92**: 391-407.
 16. Norina, A., Nurzaklah, M., Hazlin, A., Sitibalkis, B. and Salina, K. 2004. Protective effect of the ethanol extract of (zingiber officinale Roscoe) on paracetamol induced hepatotoxicity in Rats. *JSKM* **2**: 85-95.
 17. Park, K., Chun, K., Lee, J., Lee, S.S., Surh, Y. 1998. Inhibitory effect of 6-gingerol, a major pungent principle of ginger on phorbol ester-induced inflammation, epidermal ornithine decarboxylase activity and skin tumor promotion in ICR mice. *Cancer Lett.* **129**: 139-144.
 18. Raja, R., Bessem, M., Saloua, E. and Najoua, G. 2008. Biochemical evaluation of hepatic damage in subchronic exposure to malathion in rats: Effect on superoxide dismutase and catalase activities using native PAGE. *C R Biol.* **331**: 655-662.
 19. Rao, G., Glasgow, W., Eling, T. and Runge, M. 1996. Oxidative stress by organophosphorous pesticide. *Biol. Chem.* **271**: 27760-27764.
 20. Rudney, H. and Sexton, R. 1986. Regulation of cholesterol biosynthesis. *Ann. Nutr.* **6**: 245-272.
 21. Shafina, H., Suzana, M., Noor, A. and Srijit, D. 2008. Ginger extract (Zingiber officinale) has anti-cancer and anti-inflammatory effects on ethionine induced hepatoma rats. *Clinics* **63**: 807-813.
 22. Sekiya, K., Ohtani, A. and Kusano, S. 2004. Enhancement of insulin sensitivity in adipocytes by ginger. *Biofactors* **22**: 153-156.
 23. Snedecor, G. and Cochran, W. 1982. Statistical method. 7th ed., Iowa state University Press, Ame Iowa, USA.



تأثير الزنجبيل كمضاد للإلتهاب في الفئران

منى عبدالظاهر الشيمي¹، أسامة علي عبدالله²، خالد محمد فرارة¹

¹قسم الباثولوجيا الاكلينيكية - كلية الطب البيطري - جامعة بنها، ² قسم الباثولوجيا الاكلينيكية - كلية الطب البيطري - جامعة قناة السويس

الملخص العربي

أجريت الدراسة علي 60 فأر من الذكور البيضاء تم تقسيمهم إلي أربع مجموعات (15 فأر لكل مجموعة). المجموعة الأولى (مجموعة ضابطة). المجموعة الثانية (مجموعة الزنجبيل) وتم إعطائها 400 مجم من الزنجبيل/كجم من وزن الجسم. المجموعة الثالثة (مجموعة المالاثيون) وتم إعطائها 100 مجم من المالاثيون/كجم من وزن الجسم. المجموعة الرابعة (مجموعة محمية بالزنجبيل) وقد تم إعطائها الزنجبيل قبل إعطاء المالاثيون بأسبوعين. أظهرت النتائج أن هناك نقص معنوي في كل من تعبير النيوكلار فاكتر كبا بيتا ونسبة الألائين أمينوترانسفيريز والأسبرتيت أمينوترانسفيريز والكوليستيرول في المجموعة المحمية بالزنجبيل مقارنةً بمجموعة المالاثيون. وجدت زيادة معنوية في نسبة الزلال والبروتينات الكلية في الدم في المجموعة المحمية بالزنجبيل عند المقارنة بمجموعة المالاثيون. اظهر الفحص الهستوباثولوجي للكبد وجود احتقان بسيط في المجموعة المحمية بالزنجبيل مقارنةً بمجموعة المالاثيون التي أظهرت تغيرات مرضية في الكبد. أكدت هذه النتائج أن الزنجبيل مضاد قوى للإلتهاب ومضادة لتسمم الكبد في الفئران المعالجة بالمالاثيون.

(مجلة بنها للعلوم الطبية البيطرية: عدد 22 (2)، ديسمبر 2011: 249-256)